

**Use of stem cell differentiation stage factors in
bisphosphonate-associated osteonecrosis of the jaw.
Case report.**

Ennas M. , Bigliocca F.

**ennasm@libero.it
039-2300944**

LITERATURE

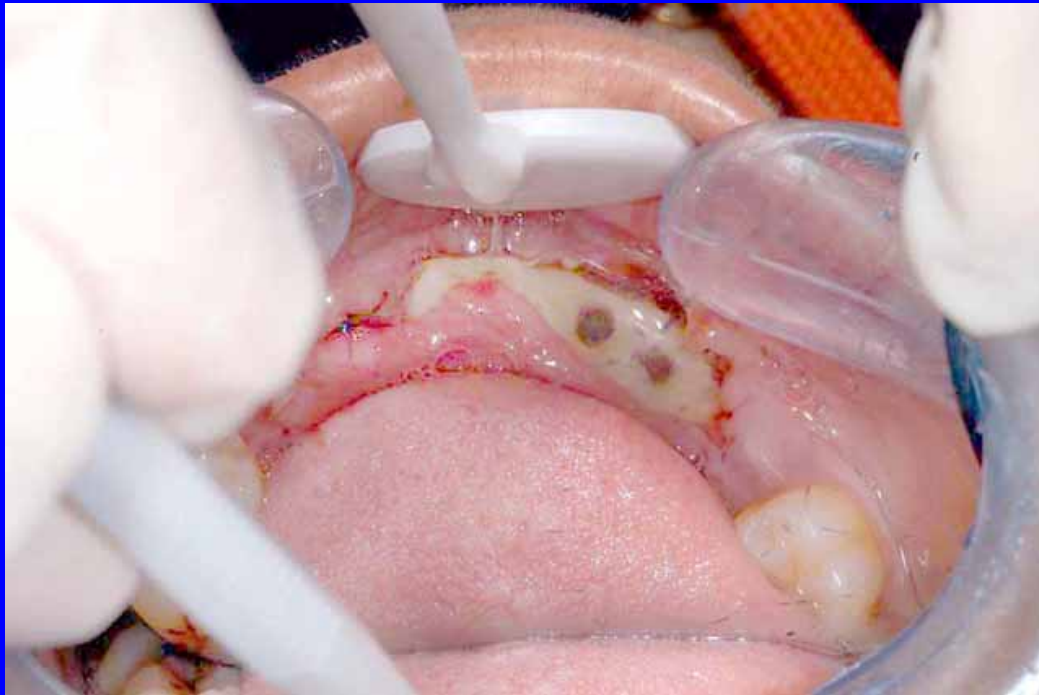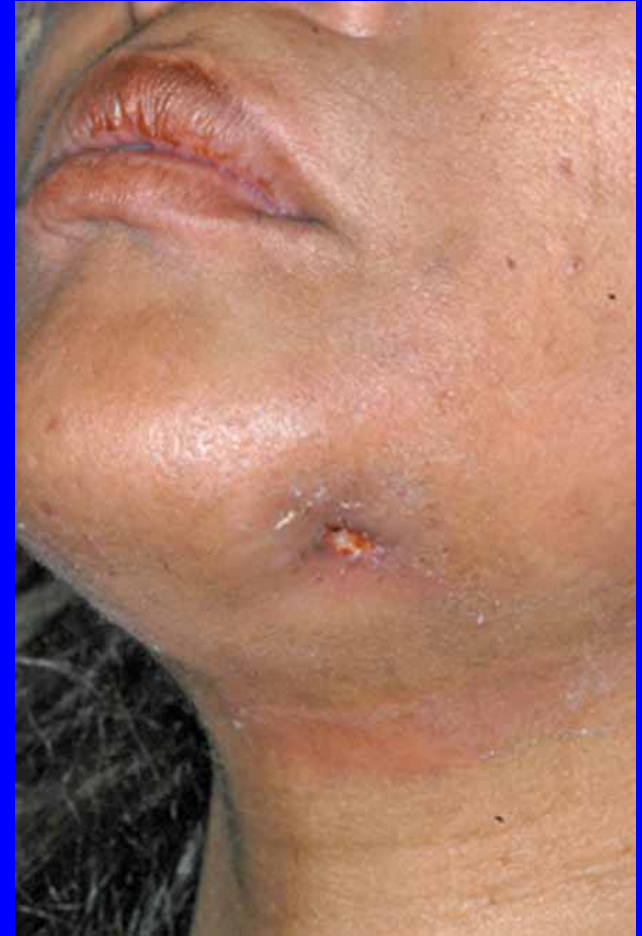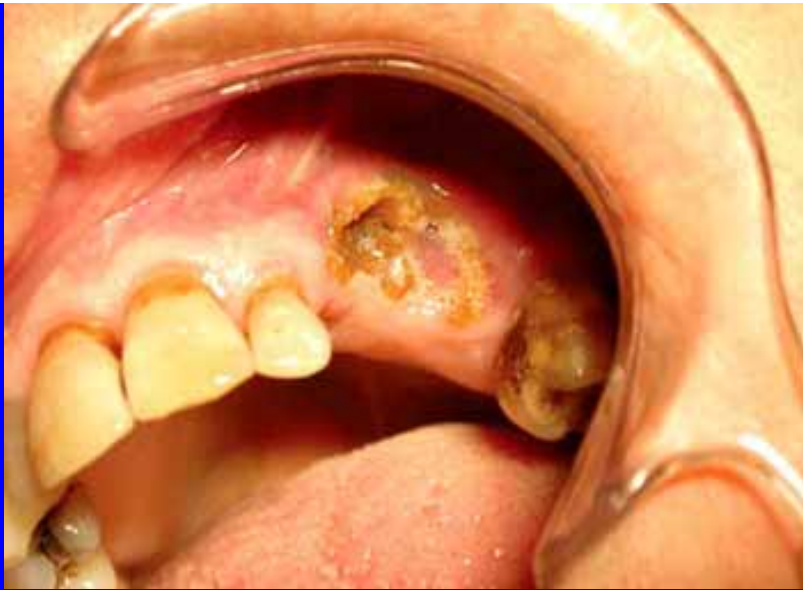Ir Med J. 2007 Mar;100(3):410-1. Links
Osteochemonecrosis of jaws and bisphosphonates.
Khosa AD, Nayyar MS, Beirne JC

A review of bisphosphonate-associated osteonecrosis of the jaws and its management.
Lam DK, Sàndor GK, Holmers HI, Evans AW, Clokie CM.

Pazianas M, Miller P, Blumentals WA, Bernal M, Kithawala P.
A review of the literature on osteonecrosis of the jaw in patients with osteoporosis
treated with oral bisphosphonates: prevalence, risk factors, and clinical
characteristics.
Clin Ther. 2007 Aug;29(8):1548-58.

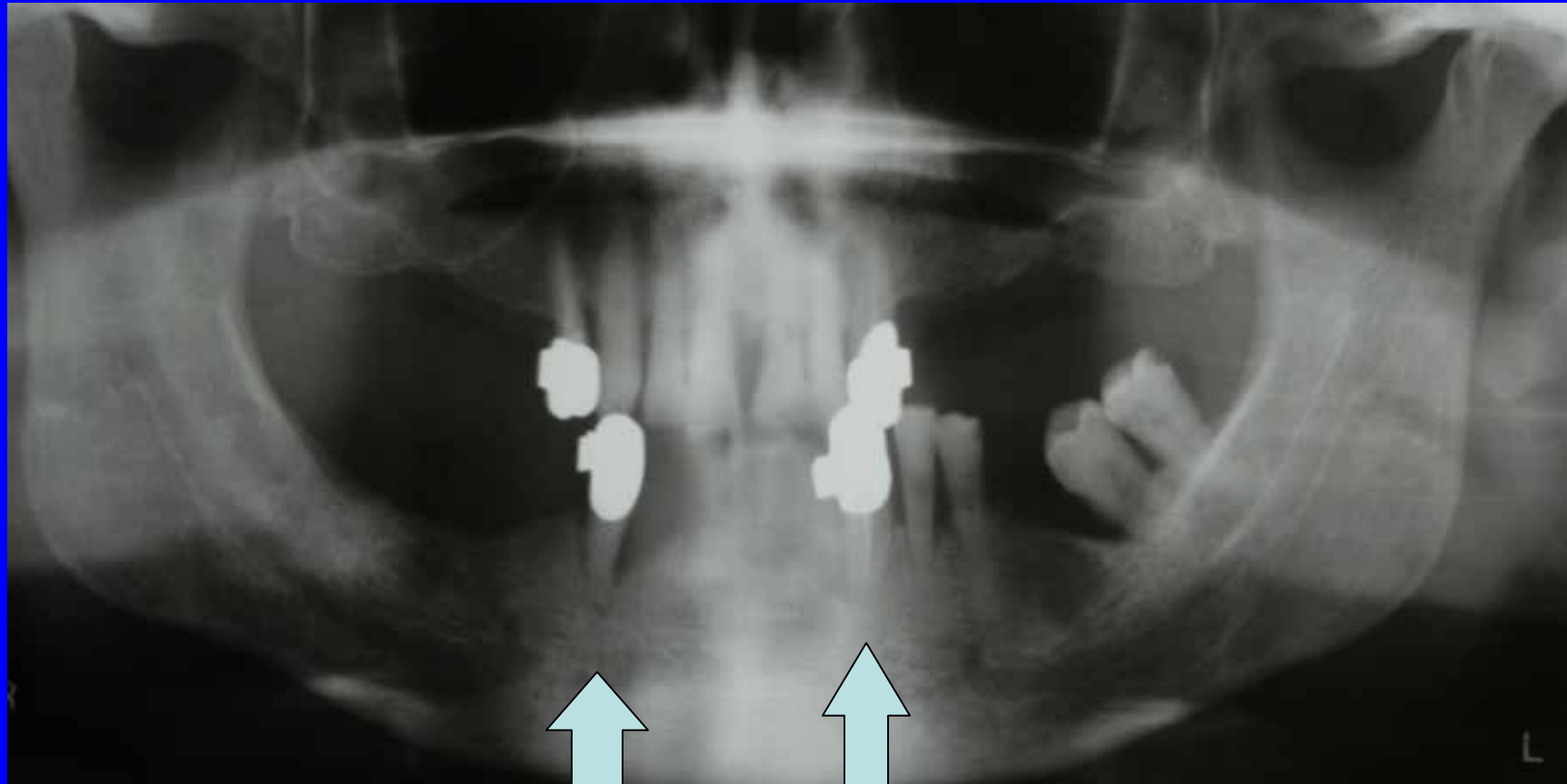
Bisphosphonate-related osteonecrosis of the jaws: a comprehensive review.
Hewitt C, Farah CS.

- Pamidronate causes osteonecrosis
- There is NO THERAPY



Case


- Male, 64 y.o., kidney cancer
- Pamidronate endovenous for 2 Years
- Parodontal infection of the jaw, with pain, teeth mobility and abscess
- Patient take stem cells differentiation stage factors



- Teeth extraction, amoxicilline + clavulanic acid for 10 days.

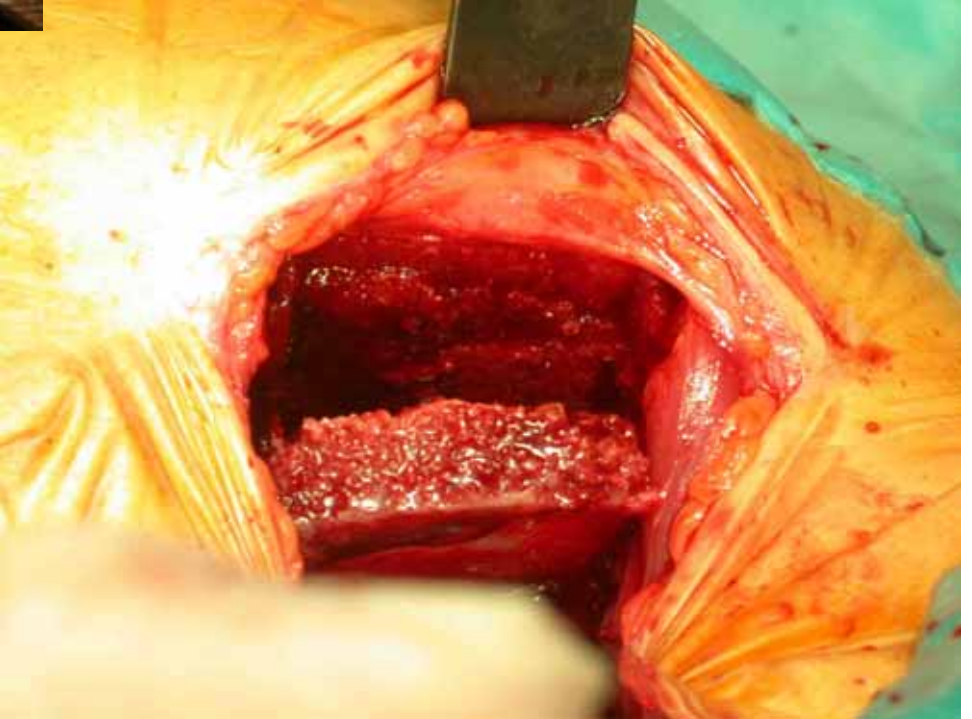
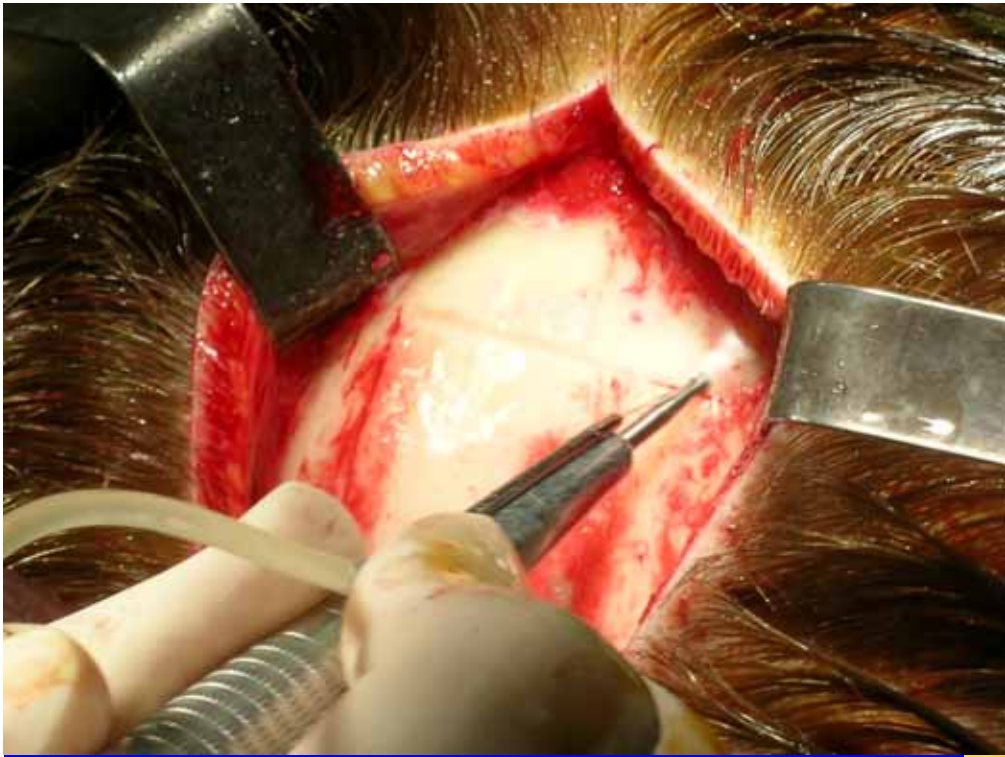- Pain and abscess remain, no gingival healing, bone exposure

- Yellow necrotic bone exposed
 - No healing



bisphosphonates osteonecrosis

Patient **ASKED** for a surgical therapy.



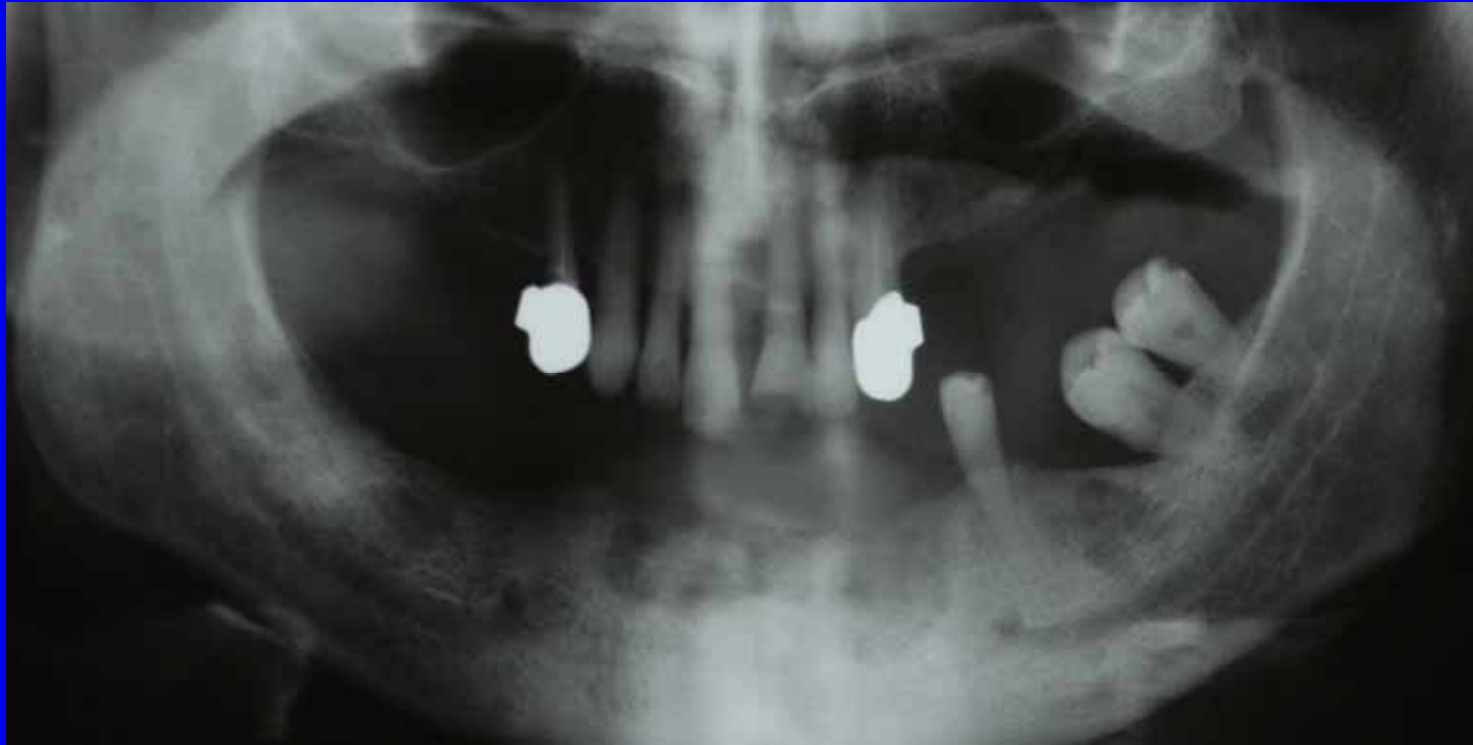
In January 2007 Dr. Ennas M. tried the surgical therapy.

Necrotic bone removed, gingival closure by double suture.

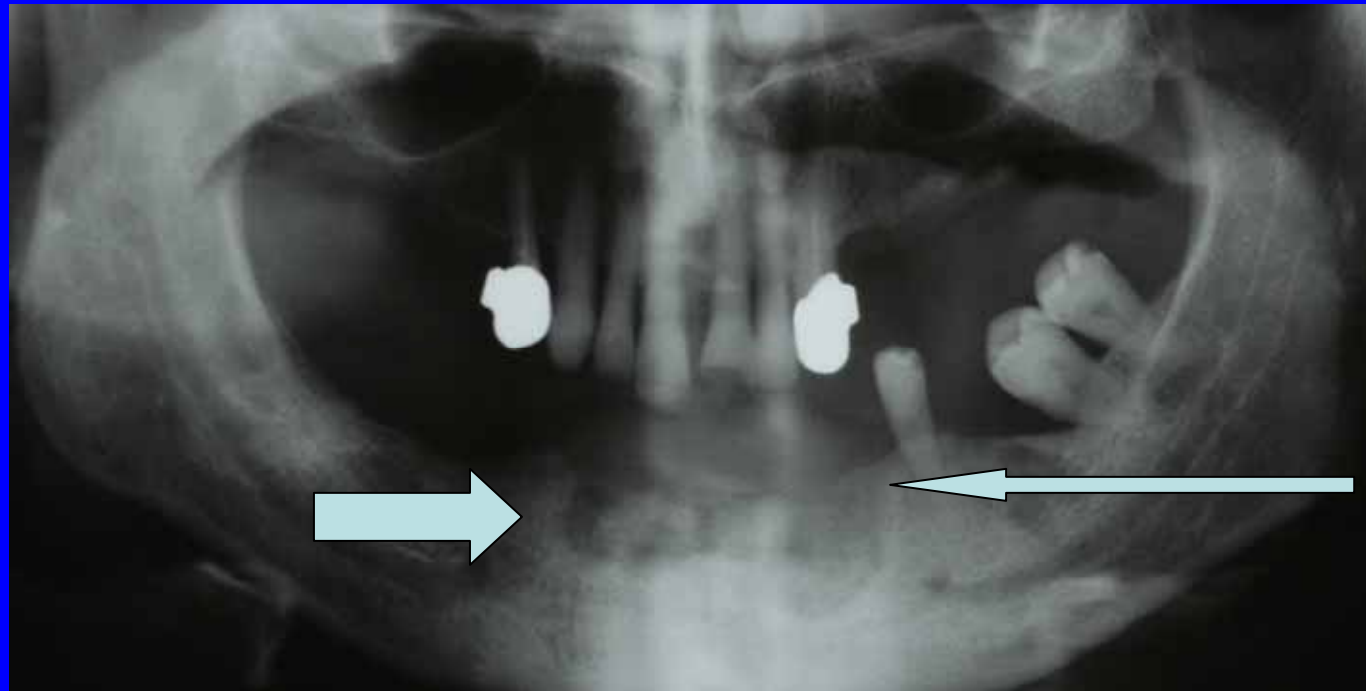
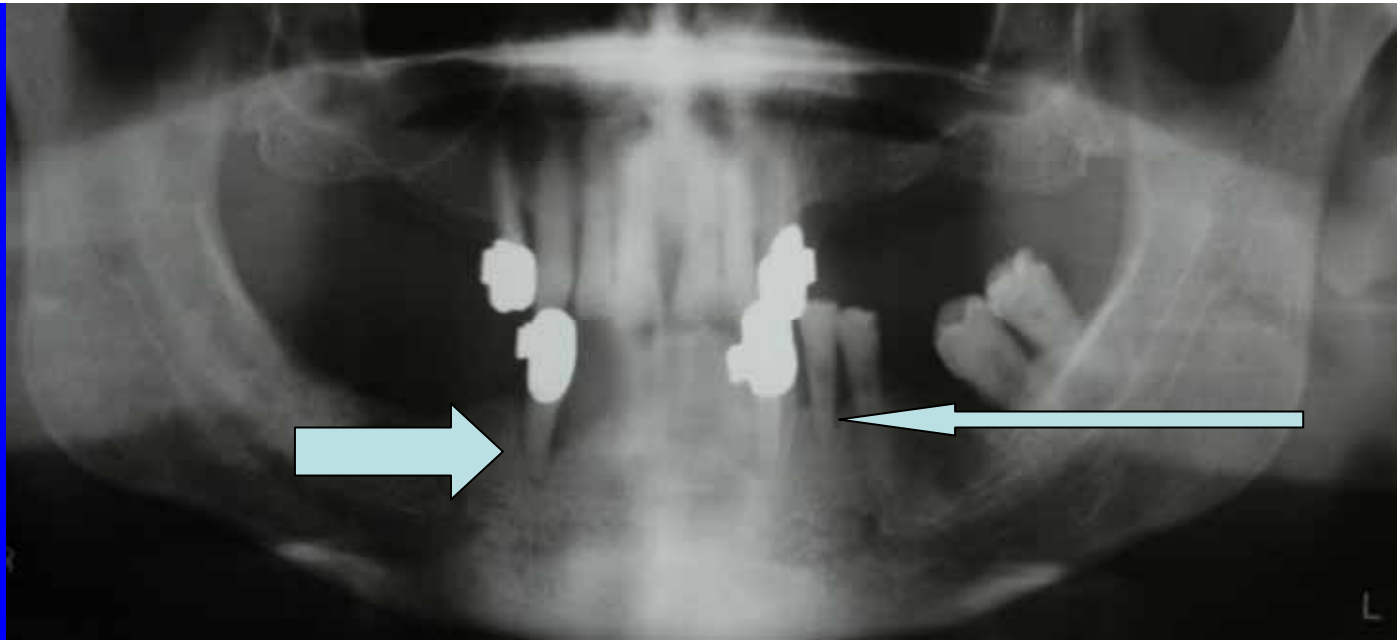
Amoxicilline+clavulanic acid, fluconazole and metronidazole for 7 days.

- 1 week later there was no pain, no abscess and no bone exposure

6 months later



No abscess, no pain and no bone exposure



Thanks for your attention

ennasm@libero.it
039-2300944